

## Variation in common carotid artery, with special reference to superior thyroid artery: A retrospective angiographic study from central India

Manisha B. Sinha<sup>1\*</sup>, Gopal Gupta<sup>2</sup>, N.N. Kolhe<sup>3</sup>, H.P. Sinha<sup>4</sup> and N. Gautam<sup>5</sup>

<sup>1</sup>Department of Anatomy, All India Institute of Medical Sciences, Tatibandh, GE Road, Raipur, Chhattisgarh, India, <sup>2</sup>Department of Anatomy, Pandit Bhagwat Dayal Sharma University of Health Sciences, PGIMS Road, Dariyao Nagar, Rohtak, Haryana, India, <sup>3</sup>Department of Radiology, NHMMI Narayana Super specialty Hospital, Dhamtari Road, Lalpur, Raipur, Chhattisgarh, India, <sup>4</sup>Department of Neurology, NHMMI Narayana Superspecialty Hospital, Dhamtari Road, Lalpur, Raipur, Chhattisgarh, India and <sup>5</sup>Department of Radiology, Aastha Diagnostics, Raipur, Chhattisgarh, India

Received: 08<sup>th</sup> August 2021; Accepted: 22<sup>nd</sup> January 2022; Published: 01<sup>st</sup> April 2022

**Abstract:** *Introduction:* Common carotid artery is a gateway to the blood supply to the head and neck region, including the brain. Previous cadaveric and few radiological studies have shown variation in the level of division and varying patterns of branches of the common carotid artery. *Aim:* The aim of the study is to investigate the prevalence of the commonest level of division of CCA in vivo through the use of CT angiography and the distance of STA (superior thyroid artery) from the level of bifurcation. *Material and method:* A total of 88 angiograms evaluated for study purpose, both right & left-sided views of the neck of all the 44 patients, have been taken into consideration during three years. Patients with intraparenchymal bleed and stroke, who had undergone CT angiography of the head and neck region, were selected and evaluated for study. *Result:* In the present study, the most frequent site of bifurcation of CCA was found to be type-II, which was at the level above the greater cornua of the hyoid bone (43.18%), and the least common site was type-V, which was at the level below the superior border of thyroid cartilage (1.13%). *Conclusion:* Variation in the bifurcation level of CCA results in variation in the origin and other parameters of other vessels (especially STA in this case) originating from the carotid arterial trunk. It leads to the possibility of misleading information to the clinicians during surgical and radiological procedures.

**Keywords:** Carotid Angiogram, Hyoid Bone, Thyroid Cartilage, Bifurcation, External Carotid Artery.

### Introduction

It is crucial to know about the normal anatomy of the carotid tree. The common carotid artery (CCA), with its two branches internal and external carotid artery, are the main feeders of blood supply to the head and neck region along with the major part of the brain.

The CCA are two in number, right and left, respectively. Right CCA is a branch from the brachiocephalic trunk, which begins in the neck behind the right sternoclavicular joint. Left CCA is a direct branch from the arch of the aorta. It begins in the superior mediastinum, slightly to the left of the center of the manubrium, and reaches to the back of the left sternoclavicular joint. Both CCAs have a similar course in the neck and,

classically, give off no collateral branch. Each one runs cranially within the carotid sheath accompanied by the internal jugular vein and vagus nerve.

Now, here on both sides, CCA is related to sternocleidomastoid muscle anteriorly and lower four transverse processes of cervical vertebrae posteriorly to reach the level of the upper border of the thyroid cartilage. These CCAs on both sides usually bifurcate at the level of the 4th cervical vertebrae into the internal carotid artery (ICA) and external carotid artery (ECA). ICA does not give any branch in the neck, but ECA gives off six branches and ends by giving two terminal branches in the upper part of the parotid region.

Similarly, the superior thyroid artery (STA), which is considered as the first anterior branch, usually arises just below the greater cornu of hyoid bone from ECA. However, there are reports in which the STA takes origin from the CCA [1-2]. The incidence of this anomaly is variable, ranging from 1% to 18% of the cases [1,3]. Hence, there has been a clinical interest in angiographical anatomy, and diagnosis or surgical techniques depend on this anatomical knowledge. The STA mainly supplies the thyroid gland and adjoining nearby tissues with its branches like an infrahyoid artery for infrahyoid muscle, superior laryngeal artery for the upper part of the larynx, sternocleidomastoid artery as a muscular branch, and lastly, cricothyroid artery [4].

Therefore, in most of the standard textbooks and literature, thyroid cartilage is an important landmark for bifurcation of the common carotid artery. Very few cases have shown that the hyoid bone is an important landmark for CCA bifurcation [5-7]. Similarly, in most of the reference books of surgery and anatomy, the superior thyroid artery has been considered typically as one of the first anterior branches from the external carotid artery quite close to its origin [4].

So, it is important to know about the course of the STA vessel, not only because it acts as a landmark for identifying the superior laryngeal nerve during thyroid surgery, but also because it is also used as a recipient vessel for microvascular free tissue transfer in head and neck surgery [8]. However, if we could see the literature, there are cases that show the variation in the branching pattern of the carotid arterial trunk. For instance, a study done by T.Vazquez et al. shows that the commonest site of origin of STA is from common carotid artery bifurcation, not from the ECA [8].

Now embryologically, all these neck vessels start developing from the aortic arch arteries during the beginning of the 4th week of intrauterine life and completely develop into adult-type by the end of the 5th week. The CCA and the first part of ICA arise from the third aortic arch. The remaining part of the ICA is formed by the cranial portion of the dorsal aorta. The ECA is also a sprouted branch from the third aortic arch

artery [9]. Therefore, any anomalous development of these arteries leads to a different pattern of branching. Studies have reported that the presence of tortuous CCA, ICA, and ECA can cause dizziness, vertigo, syncope, blackout or persistent tinnitus [10]. In fetal life and in infants, the tortuosity of carotid arteries is common. With the descent of the heart and elongation of the neck, the arteries assume the normal position. If the embryological state persists, it leads to tortuosity or kinking of the arteries [11-12].

In adults, carotid artery tortuosity is considered a risk factor for stroke but is not treated unless symptomatic. The course, variations, and angulation of the carotid arteries produce changes in the laminar flow that leads to swirls which usually evolve all the way to strictures and stenosis [13]. The position of the carotid bifurcation reflects the degree of embryological migration of ECA and is variable [14].

This variation in the branching pattern of these vessels is not uncommon and has been reported by various researchers from time to time. Besides this, many authors also reported various anomalous branching patterns of the aortic arch even and its association with the 22 q chromosomal deletion [15-16]. If we review the literature, we could find a large number of variations, an even bilateral absence of CCA [17].

Now, with the advent of complex medical and surgical problems, carotid angiography has become the preferred diagnostic tool to reduce morbidity and mortality. These angiographic procedures could assess the atherosclerotic plaque, thrombosis, stenosis, dissection, aneurysm and other vascular lesions of common, internal, and external carotid arteries. Sometimes, dissection of vessels may be mistaken for stenosis because of similar radiological findings resulting in misleading information to the clinician. Therefore, knowledge of the origin, course, and variation of these vessels has great importance in surgical and radiological examinations.

Therefore, adequate knowledge of the various surgical and invasive procedures of these

bigger vessels through angiography is a must. Due to the increase in the incidence of arteriosclerotic vascular disease and other pathological conditions, the importance of the diameter of various great vessels has its own significance. These diameters give us better quantitative parameters for making better diagnoses through these angiographic procedures. For this reason, the diameter of various vessels has been measured and compared for sexual dimorphism and their significance on the right and left sides.

Thus, the aim of the study is to add substantiation in variation of bifurcation level of the common carotid artery, level and pattern of origin of superior thyroid artery, and other parameters through the angiographic procedure. In a cadaveric study, the level of division of CCA on both anterior (cartilaginous level) and posterior side (vertebral level) may change in the disarticulated head and neck. These angiographic procedures are increasingly in use nowadays. Hence, knowledge through angiographic studies would be much beneficial to us in defining various parameters. On CT angiogram, these structures and their parameters are the same as they are seen in vitro.

### Material and Methods

In this retrospective study, samples were consecutively selected. The cases that were diagnosed as cases of transient ischemic attack (TIA), ischemic stroke and non-hypertensive intraparenchymal bleed were enrolled. The patients who presented to the hospital from March, 2015 to March, 2018 were recruited in the study. Out of forty four cases, thirty eight were ischemic stroke, four were TIA and two were intraparenchymal bleed. Three hundred eighty patients of stroke were excluded on account of occlusive pathology in carotid circulation.

Patient with block were excluded from the study. Total eighty eight sides were evaluated. Bilateral evaluation makes it easier and helpful in comparing the right-sided vessels with left side. According to sex distribution we examined CT angiogram of 31 males and 13 females with age range from 27 years to 73 years (mean age-51.1years). Those patients, who have constriction and narrowing of the vessels, were excluded from study because of difficulty ingenerating images.

The study was approved by the ethical committee, and written informed consent was taken from the patients. In the present study, retrospective data were evaluated, and then its relevance was discussed. The methods used in this study were performed in accordance with internationally established guidelines and regulations.

In all these 44 patients, bilateral angiograms have already been performed for a clinical diagnosis of intracranial bleed or stroke.

*Technique of Angiography:* Patients selected for CECT Angiography were scanned with a 64 slice GE Optima CT 660 CT scanner. The parameters set for the examination were, voltage-120 KVp, Qref-auto low dose mA, collimation - 64 X 0.625 mm, pitch factor - 0.98, and rotation time - 0.5sec. CECT Angiography of the entire neck and head from the aortic arch to the vertex was obtained in supine position using 100 ml of intravenously administered Iodinated, iso-osmolar, non-ionic contrast material (Omnipaque300) with a dual-head power injector for 20 seconds at a rate of 5.0 ml/sec. This has been followed by 20 ml of saline chaser using a bolus-tracking technique to prevent thrombus formation.

A source as well as MPR (multiplanar reformation), MIP (maximum intensity projection), and VR (volume rendering) image were reviewed at window settings appropriate for vessels (WL-120HU; WW-400HU). Anatomy and other parameters were evaluated in both anterior and lateral projections for all the vessels which were studied.

First of all, visualization of bifurcation level of CCA was observed on both anterior and posterior sides. The bifurcation level of CCA was categorized into five categories (Type-I to V) on both the anterior (cartilaginous level) and posterior side (vertebral level). Cartilaginous level correlating the level of arterial bifurcation with the level of the hyoidbone or laryngeal cartilages and vertebral level correlating the bifurcation of CCA with the corresponding vertebral level. On observing the posterior side i.e. vertebral level, the midpoint of each cervical vertebra was taken into consideration for measurement

criteria. Bilateral evaluation makes it easier and helpful in comparing the right-sided vessels with the left side. The result of various diametric parameters of CCA, ICA, and ECA were observed and compared. This includes Minimum diameter (Min), Maximum diameter(Max), Average diameter(Avg. dia.), and Standard deviation(Std. Dev.) of a total number of cases in Male(M), Female(F), and Right(R) and Left(L) sides. Their average diameter and standard deviation were also calculated and are shown in tables. All the measurements were performed using millimeters (mm) as the unit.

Besides this, as mentioned in the majority of the medical books and in various research publications, STA has been considered to have the commonest and constant origin from ECA. However, some previous studies also showed variations in the origin of STA. Some authors classify the variation in branching pattern and anatomy of STA on the basis of cadaveric study and some even did it with the angiographic method. The majority of them found it as a vast and complex study. So, here we used CECT angiographic procedure for more quantitative and qualitative data about these parameters for applying them in various clinical settings. In our study, STA was categorized into four types, from type I to IV, on the basis of its origin from various great vessels of the neck. STA was also measured for their diameter at the level of origin and its distance of origin from the level of bifurcation through CT angiography. All these data were compiled and compared in both sexes and on both sides for their statistical significance.

After recording all the findings, the following parameters were studied:

- A. Bifurcation level of CCA both on the anterior side (Cartilaginous level), and posterior side (vertebral level). Each side was again categorized into five Types (Type I to V), Anterior levels were (Cartilaginous level) Type I: at the level of the body of the hyoid bone, Type II: -above greater cornua, Type III: at greater cornua, Type IV: between the hyoid bone and thyroid cartilage, and Type V: at the level of the thyroid cartilage. Posterior levels were midpoint of each vertebral body (vertebral level) Type I: from

C2-C3 level, type II: from C3-C4 level, Type III: C4-C5, Type IV: C5-C6 level, and Type V: C6-C7 level.

- B. Diameters of CCA, ICA, and ECA were obtained.
- C. Branching pattern of superior thyroid artery was also categorized as Type I: From Common carotid artery (CCA), Type II: From bifurcation of the common carotid artery (Trifurcation level); Type III: From External carotid artery (ECA); Type IV: From common trunk as thyrolinguofacial artery from ECA (CT). Diameter of superior thyroid artery and its distance from bifurcation level of CCA.

*Statistical analysis:* Results of measurements were analyzed by 't' tests (using SPSS version 15), and differences between means were considered statistically significant when  $P < 0.05$ .

## Results

Of these bilateral angiograms (88 sides) anteriorly, the most common level of bifurcation was the level above the greater cornu of the hyoid bone (43.18 %), and the least common was the level below the superior border of thyroid cartilage (2.27%). The most common level of bifurcation was corresponding to the level of C3-C4 vertebrae (45.45%), and the least common was shared by two groups, first, at the level of C5-C6 and second at the level of C6-C7 (2.27%). There was no significant difference in the bifurcation level of CCA between right and left side as well as between males and females. The rest of the observations are shown in table 1.

The diameter of various neck vessels was found to range from 5.3mm to 9.5mm in case of CCA, 3.6mm to 5.5mm in case of ECA, and 3.4mm to 8.5mm in the case of ICA. There were no statistically significant differences by sex or by the side in any of these vessels. The t-value and p-value calculated among these groups were found to be nonsignificant.

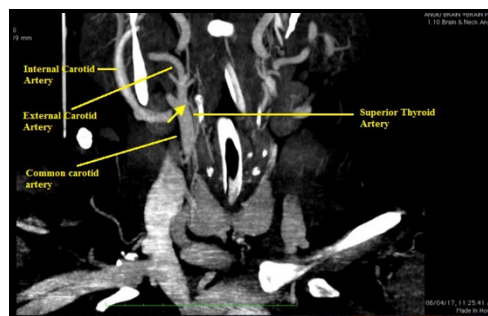
Categories	Anterior (cartilagenous level)	No. of Cases	% of cases	Posterior (vertebral level)	No. of Cases	% of cases
Type I	Body of hyoid bone	14	15.9%	C2-C3	16	18.18%
Type II	Above the greater cornua	38	<b>43.18%</b>	C3-C4	40	<b>45.45%</b>
Type III	At the greater cornua	30	34.09%	C4-C5	28	31.8%
Type IV	Between hyoid bone and thyroid cartilage	5	5.7%	C5-C6	2	2.27%
Type V	Below superior border of thyroid cartilage	1	1.13%	C6-C7	2	2.27%

Categories	Level of origin of STA	No. Of cases (out of 88)	% of cases	Incidence
Type I	From CCA bifurcation ( <b>Trifurcationlevel</b> )	48	54.54%	Most common
Type II	From Common carotid artery (CCA)	5	5.68%	
Type III	From External carotid artery (ECA)	34	38.63%	
Type IV	From common trunk (CT) from ECA as thyrolinguofacial trunk	1	1.13%	Least common

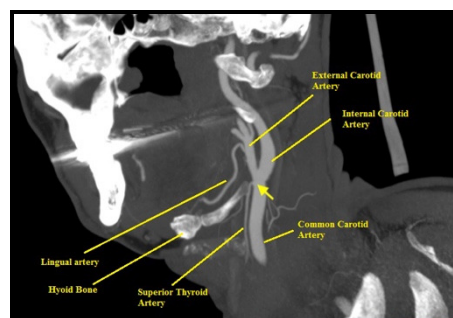
In Table 2, the result showed that in 48 of the 88 cases (54.54%), the STA was found to arise at the level of carotid bifurcation (trifurcation level); and was classified as type I (Fig. 1). With the presence of only one case of the 88 cases (1.13%), where STA was found to arise from (CT) common trunk of ECA as thyrolinguofacial trunk, was classified as Type IV (Figure. 4).

The rest of the types where STA originated from CCA itself or ECA were classified as Type II (Figure. 2) and Type III (Figure. 3), respectively, as shown in table 2 and discussed later. P-value and t-value amongst male(M), females(F), and right(R), left(L) sides were found to be not significant. All the measurements were in the unit of mm.

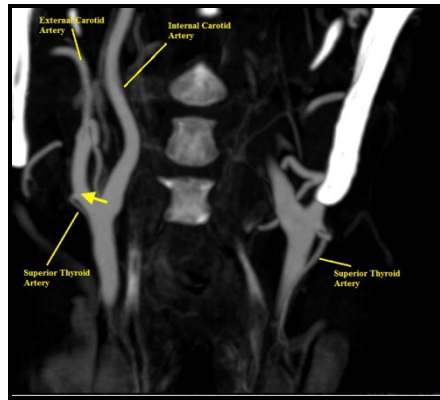
**Fig-1:** Arrow showing origin of STA from bifurcation point of CCA (Type I)



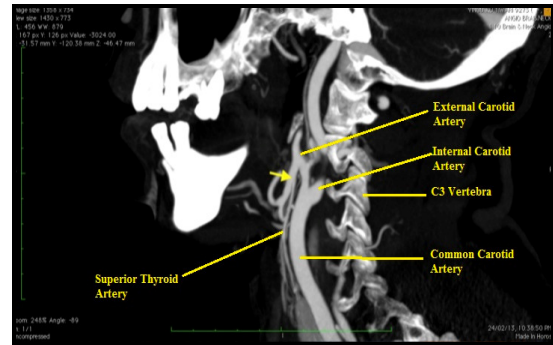
**Fig-2:** Arrow showing origin of STA from CCA (Type II)



**Fig-3:** Arrow showing origin of STA from ECA. (Type III)



**Fig-4:** Arrow showing origin of STA as a common trunk (CT) in the form of Thyrolinguofacial trunk. (Type IV)



Parameters	Diameter of STA (mm)					Distance of STA from the Bifurcation level (mm)				
	Total	M	F	R	L	Total	M	F	R	L
Min.	0.34	1	0.34	0.34	1	0	0	0	0	0
Max.	2.5	2.5	2	2	2.5	8.8	8.8	8	8.3	8.8
Mean Dia.	1.62	1.69	1.45	1.63	1.61	2.06	2.81	2.94	2.8	1.65
SD	0.37	0.32	0.45	0.4	0.35	3.02	3.28	1.91	2.94	2.99
T value		0.06		0.88			0.41		0.14	
P value		0.95		0.37			0.68		0.88	

The level of origin of STA in terms of distance from bifurcation point of CCA and their diameters are shown in table 3. Out of 88 cases in total, the number of STA arising from the level of bifurcation (Trifurcation level) was forty-eight. In 34 cases, STA artery arises from ECA above the level of bifurcation level, but no STA was found to be taking origin from ICA artery. Finally, 5 cases of STA arose from CCA, a level below the bifurcation. Only one case STA arose as a common trunk (CT) from ECA, 1.8 mm above the level of bifurcation level.

Now the result shows that the diameters of STA were ranged from 0.34mm to 2.5mm, with an average value of 1.62mm and a standard deviation of 0.37mm. There was no statistically significant difference between the diameter of both sexes and on the right and left sides. The distance of STA from the bifurcation level was ranging from 0.0mm to 8.8mm, with an average value of 2.06mm and a standard deviation of

3.02mm. Here also, we could not find any significant difference between the two sexes and the right and left sides of the neck.

**Discussion**

Ligation of the external carotid artery for maxillofacial trauma or surgeries for oral cavity tumors is often done above the origin of the superior thyroid and below the lingual artery. Collateral anastomotic channels do exist between the external carotid artery (ECA) and internal carotid artery (ICA). So, ligation of the external carotid has no serious sequelae unless the internal carotid is injured during the operation [8]. The variation in the level of bifurcation is also well documented. A high level of bifurcation has also been reported earlier.

Gluncic et al, reported the unilateral high level of bifurcation at the level between C2-C3 cervical vertebrae on the right side in the

Caucasian male[6]. Similarly, Thwin et al. also reported a bilateral high level of bifurcation at the C2 level on the right side and C3 level on the left side in a cadaver from Malaysia[7]. According to the literature available, bifurcation of CCA at the level of the C2 is 1%[8], and in our study also, only 1 case (1.13% of cases) was found to be bifurcating at the lower level of C2. In our angiographic study, the incidence of variation at the C2-C3 cervical level was 18.18%.

Chitra R reported a case where CCA divided at the level coinciding with the level of the tip of the hyoid bone [5]. Kishve SP et al., reported a case in which the bifurcation was at a level 1cm above the greater cornu of hyoid bone on both sides [14]. In our study, this typeII category has a prevalence of 43.18%, with the maximum number of cases falling in this category (Cartilaginous level). The Developmental explanation for this high level of bifurcation is not easy. It could be because of bifurcation at the level of the second aortic arch instead of the third arch during development [9]. The presence of a large number of Type II cases in our study could not rule out the possibility of more accurate angiographic measurements rather than previous cadaveric measurements. Also, the possibility of different ethnic origins could not be ruled out.

Gluncic et al in their case report, also showed that the diameter of CCA at its origin was 7.8mm and 2mm below the bifurcation, was 10.5 mm [6]. In our study, the average diameter of CCA was found to be 6.71mm. For the purpose of comparison, we could not find much data on the diametric measurement of carotid vessels in previous works of literature. As angiographic methods are gaining importance in diagnostic fields, the knowledge of variations of various vessels originating from carotid vessels becomes essential. The awareness of variation such as their branching pattern, their absence, anastomoses, and collaterals should be well understood.

The location of STA, its branching pattern, and variation of the origin are quite well known. Normally, it arises from ECA as a separate anterior branch, but it was also reported by many that it has got different origins [18-19]. The data available here from the angiographic study was very few. Most of the available data have been from the cadaveric or autopsy studies used here

for comparison. In our study, we found that the most common type of STA variation was typeI (54.54%), in which STA arose from CCA bifurcation. It may be named as trifurcation level. Our findings were very much similar to the autopsy finding of Vazquez et al. in 330 neck hemisections, in which CCA bifurcation (49% cases) was the most common site for STA origin [8].

One more cadaveric study was done by Ozgur et al., in 20 Anatolian adults, in which 40% of cases were found to be the typeI category [12]. However, there are studies that differ from our study. Lucev et al. reported in their study, in which only 22% of cases STA originated from CCA bifurcation [20]. Similarly, an Indian angiographic study was done by P Gupta et al., in 25 cases, in which CCA bifurcation was the second most common site of origin of STA and out of which 21.5% cases were present on the right and 18.5% on the left side respectively [21]. In one more Indian study done by Anitha et al., STA origin from CCA bifurcation was noted to be 19% [22].

Now, most of the literature has demonstrated that the most common origin of STA is from ECA. As it was well documented in the studies done by Adachi, Poissel, and Golth [23-24], and Indian researchers like Gupta P, Anitha, Sanjeev et al [21-22, 25]. Our study did not match with the findings of these authors. In the present study, the incidence of Type III was 38.6% in which STA arose from ECA. Another researcher, Lucev et al., also found that in 23% of cases, STA arose from ECA. Both the studies showed that the type III category was the second most common type, as found in our study [20].

Documentation of STA taking origin from other arteries has also been reported in the literature. Cases in which STA originates from CCA (TypeII) were very few in our study (5.68% only). In contrary to the finding by the earlier authors, who reported the incidence of TypeII to be the most common (47% by Lucev et al.) and second most common type (26.6% by Vazquez et al.) respectively [8,26]. Even Hollinshead found 45 % of cases of STA were arising from CCA [4].

We also found one rare case of Type IV variety (1.13%), in which STA arose as a common trunk (CT) with facial and lingual arteries (Thyro-linguofacial trunk) from ECA. Such findings were reported by Zumre and colleagues in their study on human fetuses, and incidence was 2.5% among all cases. Such variation has also been reported as a case report by various authors like Ozgur et al., Motwani R, Bhudhiraja V et al., Koneko et al [2, 18, 26-27].

Now, regarding the diameter of STA, our average value of 1.64mm, did not concede with the mean value of 0.26cm Vazquez et al., who measured the STA diameter in 330 cases [8]. Our value of maximum diameter 0.25cm was very close to the mean value of Vazquez, which could also support in view of racial discrepancy among the two groups. Regarding the distance of STA from the level of bifurcation, it varied from 7.9mm above when it took origin from ECA (Type-III) and 8.8mm below in cases where STA arose from CCA (Type-II).

Therefore, in our study, STA originated from arteries other than ECA in approx. 59% of cases. There are previous such studies also, which were in support of our study. Thus, by simply classifying the origin of STA and bifurcation

level of CCA at various levels, we make the things easier for a clinician and even anatomist to understand the various branching patterns easily. It might enhance the precision and decrease the mortality and morbidity during head-neck surgeries. By knowing the various diameters, microcatheterization of these small vessels could be done with much compliance.

### Conclusion

The present study shows that in most of the cases, CCA bifurcation was above the greater cornu of hyoid bone (43.18%), and in 54.54% cases, STA was found to arise at the trifurcation level. So, such results in the branching pattern of the carotid tree will be very useful among various radiological angiographic studies. Also, by knowing the various variations among these vessels, it would be useful for the surgeons to proceed for vascular surgeries with ease. The present study may also be utilized by radiologists to avoid any errors during clinical-radiological correlation. Therefore, prior knowledge of these variations should be a must and without which radiological evaluation or surgical proceedings could lead to a fatal outcome.

**Financial Support and sponsorship:** Nil

**Conflicts of interest:** There are no conflicts of interest.

### References

1. Akyol MU, Koc C, Ozcan M, Ozdem C. Superior thyroid artery arising from the common carotid artery. *Otolaryngol. Head Neck Surg.* 1997; 116:701.
2. Koneko K, Akita M, Murato E, Imai M, Sowa K. Unilateral Anomalous left common carotid artery: A case report. *Ann Anat.* 1996; 178:477-480.
3. Lemaire V, Jacquemin G, Medot M, Fissette J. Thyrolingual trunk arising from the common carotid artery: A case report. *Surg Radiol Anat.* 2001; 23:135-137.
4. Hollinshead WH. Anatomy for surgeons. Vol.1.Head and Neck. *Hoeber Harper International, Philadelphia.* 1966; 459.
5. Chitra R. Trifurcation of right common carotid artery. *Indian J Plastic Surg.* 2008; 41:85-88.
6. Gluncic V, Petanjek Z, Marusic A, Gluncic I. High bifurcation of CCA, anomalous origin of ascending pharyngeal artery and anomalous branching pattern of external carotid artery. *Surgical Radiol Anat.* 2001; 23:123-125.
7. Thwin SS, Soe MM, Myin TM, Than M, Lwin S. Variations of the origin and branches of the external carotid artery in a human cadaver. *Singapore Med J.* 2010; 51(2):40-42.
8. Vazquez T, Cobiella R, Maranillo E, Valderrama FJ, McHanwell S, Parkin I, Sañudo RJ. Anatomical variation of superior thyroid and superior laryngeal arteries. *Head & Neck.* 2009; 10:1078-1085.
9. Sadler TW. Langman's medical embryology, 12th edn. *Williams & Wilkins, Baltimore.* 2012; 185-186.
10. Aleksic M, Schütz G, Gerth S, Mulch J. Surgical approach to kinking and coiling of the internal carotid artery. *J CardiovascSurg.* 2004; 45(1):43-48.
11. Agrawal R, Agrawal S. Dangerous anatomic variation of internal carotidartery – a rare case report. *Int J Anat Variat.* 2011; 4:174-176.
12. Shanley DJ. Bilateral aberrant cervical internal carotid arteries. *Neuroradiology.* 1992; 35:55-56.
13. Leipzig TJ, Dohrmann GJ. The tortuous or kinked carotid artery: pathogenesis and 'clinical considerations. A historical review. *SurgNeurol.* 1986; 25:478-486.



14. Kishve PS, Kishve SP, Joshi M, Aarif SMM, Kalakoti. An unusual branching pattern of common and external carotid artery in a human cadaver: a case report. *Australas Med J*. 2011; 4(4):180-182.
15. Momma K, Matsuoka R and Takao A. Aortic arch anomalies associated with chromosome 22q11 deletion (Catch 22); *Pediatric Cardiology*. 1999; 20(2):97-102.
16. Shivkumar GL, Pamidi N, Somayaji SN, Nayak S, vollala VR. Anomalous branching pattern of aortic arch and its clinical application. *Singapore Medical Journal*. 2010; 51(11); e182.
17. Rajeshwari MS. bilateral absence of common carotid arteries with variant branching pattern of aortic arch. *Int J Anat Res*. 2013; 02:107-110.
18. Motwani R, Jhaharia SK. Variant Branching pattern of superior thyroid artery and its clinical relevance: A case report. *Journal of clinical and diagnostic Research*. 2015; 9(6): 5-6.
19. Zumre O, Salbacak A, Cicekcibasi A E, Tuncer I, Seker M. Investigation of the bifurcation level of CCA and variation of the branches of ECA in human fetuses. *Ann Anat*. 2005; 187(4):361-369.
20. Lucev N, Babinac D, Maric I, Drescik I. Variation of the great arteries in the carotid triangle. *Otolaryngol Head Neck Surg*. 2000; 122:590-591.
21. Gupta P, Bhalla AS, Thulkar S, Kumar A, Mohanti BK, Thakar A et al. Variation in superior thyroid artery. A selective angiographic study. *Indian J Radiol Imaging*. 2014; 24:66-71.
22. Anitha T, Dombe D, Asha K, Kalbande S. Clinically relevant variation of superior thyroid artery: An anatomical guide for neck surgeries. *Int J PharmBiomed Sci*. 2011; 2:51-54.
23. Adachi B. The arterial system of Japanese. Vol.1. *Kyoto: Kenkyusha*. 1929; 58-62.
24. Poissel S, Golth D. Variability of large arteries in the carotid triangle. *Wien Med Wochenschr*. 1974; 15:229-232.
25. Sanjeev IK, Anita H, Ashwini M, Mahesh U, Rairam GB. Branching pattern of external carotid artery in humans. *J ClinDiagn Res*. 2010; 4:3128-3133.
26. Ozgur Z, Govsa F, Celik S, Ozgur T. Clinically relevant variation of superior thyroid artery: An anatomical guide for surgical neck dissection. *SurgRadiol Anatomy*. 2009; 31:151-159.
27. Bhudhiraja V, Rastogi R. Variant origin of thyrolingual trunk from left common carotid artery. *International journal of Anatomical variation*. 2010; 3:44-45.

**Cite this article as:** Sinha MB, Gupta G, Kolhe NN, Sinha HP and Gautam N. Variation in common carotid artery, with special reference to superior thyroid artery: A retrospective angiographic study from central India. *AI Ameen J Med Sci* 2022; 15(2):92-100.

This is an open access article distributed under the terms of the Creative Commons Attribution-Non Commercial (CC BY-NC 4.0) License, which allows others to remix, adapt and build upon this work non-commercially, as long as the author is credited and the new creations are licensed under the identical terms.

\*All correspondences to: Dr. Manisha B. Sinha, Additional Professor, Department of Anatomy, All India Institute of Medical Sciences, Tatibandh, GE Road, Raipur, Chhattisgarh, India. E-mail: manishab80@gmail.com